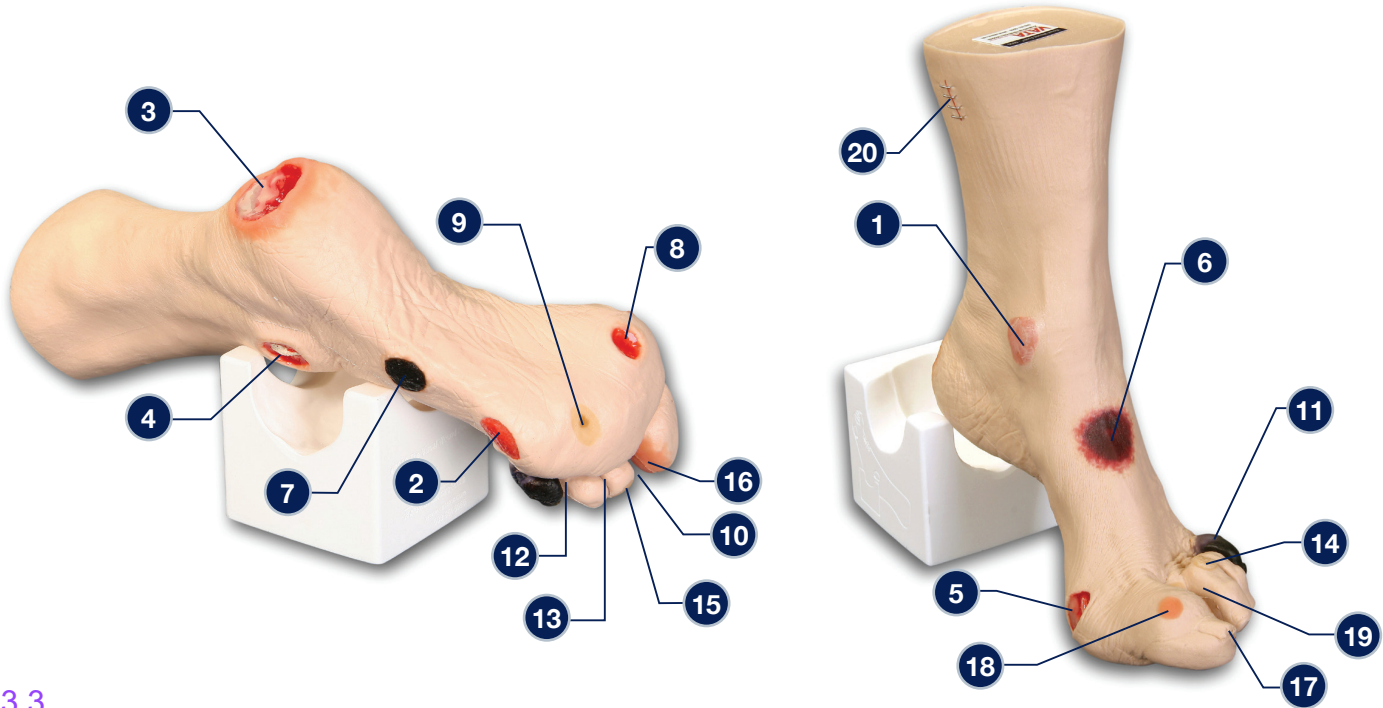


## Wilma Wound Foot™ – 0950



### 3.3.

The following wounds\*, pressure injuries\* and foot abnormalities are presented on Wilma Wound Foot™

- |  |  |
|--|--|
| 1 Stage 1 pressure injury on the medial malleolus  | 10 Amputated 2nd toe   |
| 2 Stage 2 pressure injury on the lateral foot (behind the 5th toe)                                   | 11 Dry gangrene of the 5th toe, due to ischemia                  |
| 3 Stage 3 pressure injury on the heel with infection   | 12 Interdigital maceration between the 4th and 5th toe           |
| 4 Stage 4 pressure injury on the lateral malleolus with exposed tendon and bone (with osteomyelitis) | 13 Partial thickness wounds between 3rd and 4th toe at 1st joint |
| 5 Stage 4 pressure injury on the medial foot (behind the great toe) with exposed tendon and slough   | 14 Corn at base of 3rd toe                                       |
| 6 DTPI (Deep Tissue Pressure Injury) on top of foot with "mushy/boggy" feel when palpated            | 15 Callus at tip of 3rd toe                                      |
| 7 Eschar (unstageable) on lateral foot   | 16 Ingrown toenail on the medial aspect of the great toe         |
| 8 Full thickness ulcer, plantar, 1st digit, probable diabetic neuropathic etiology                   | 17 Fungal thickened toenail on the great toe                     |
| 9 Callus under the 4th metatarsal phalangeal joint   | 18 Blister on great toe at the first joint                       |
|  | 19 Hammer toes - 3rd, 4th and 5th toes                           |
|  | 20 Skin stapled wound  |

\* We have included the most likely etiology-based descriptions, but realize many wounds can appear in the same location, having different etiologies. The definitive diagnosis is up to the clinician and interprofessional wound care team.

**Care Instructions:** To clean your model VATA recommends soap and warm water. Some customers have found applying a barrier/skin prep can give them the adhesion they are looking for.

